
CURRICULUM VITAE

Dr. D. Francisco Raga Baixauli.

CURRICULUM VITAE

Nombre completo:

Francisco Raga Baixauli.

Fecha de nacimiento:

28/Diciembre/1965.

Lugar de nacimiento:

Valencia. España.

Nacionalidad:

Española.

Estado civil:

Casado.

Dirección y teléfono:

**Pedro Aleixandre nº 57-7.
Valencia. CP:46006.
Telefono: 96-3224090.**

ESTUDIOS REALIZADOS

Educación primaria:

**Colegio El Vedad.
1972-1980. Valencia. España.**

Educación secundaria:

**Colegio Sagrado Corazon HH. Maristas.
1980-1983. Valencia. España.**

**Charles B. Aycock. H.S.
1983-1984. Goldsboro. NC. U.S.A.**

CURRICULUM VITAE

Educación superior:

**Universidad de Valencia.
Facultad de Medicina y Cirugía.
1984-1990. Valencia. España.
Título obtenido: **Licenciado en Medicina y
Cirugía.**
Calificación: **Sobresaliente.****

Doctorado.

**Universidad de Valencia.
Facultad de Medicina y Cirugía.
Departamento de Pediatría, Obstetricia y
Ginecología.1992.**

Título obtenido: **Doctor en Medicina y Cirugía.**

Calificación: **“Cum Laude”.**

CURRICULUM VITAE

EXPERIENCIA LABORAL

Hospital Clínico Universitario.

Médico interno residente. Especialista en Obstetrícia y Ginecología.
1992-1996. Valencia. España.

Instituto Valenciano de Infertilidad.

1996. Valencia. España.

Stanford University Medical Center.

Postdoctoral Research Fellow.
Reproductive Endocrinology Laboratory.
1997-1998. CA. USA.

Stanford University Medical Center.

Postdoctoral Research Fellow.
Advance operative Laparoscopy and
Hysteroscopy.
1997-1998. CA. USA.

Hospital Clínico Universitario.

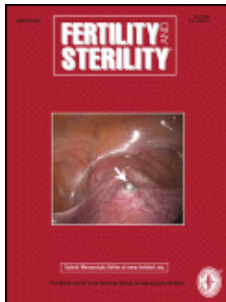
Médico Adjunto. Especialista en Obstetrícia y Ginecología.
1999-2012. Valencia. España.

Hospital Clínico Universitario.

Jefe Clínico.
2012-2013. Valencia. España.

CEGIOB.

Médico especialista en Obstetrícia y Ginecología.
1998-2013. Valencia. España.

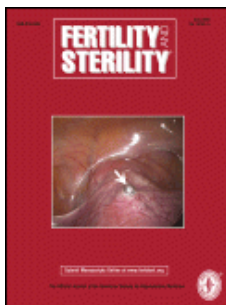


Fétil. Steril.

RAGA,F; SANZ-CORTES M, CASAÑ EM, BUERGUES O, BONILLA-MUSOLES F.

Cotyledonoid dissecting leiomyoma of the uterus.

Fertil. Steril. 2008. 00:000-000.

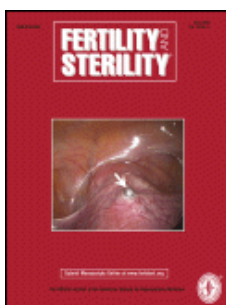


Fétil. Steril.

RAGA,F; BONILLA-MUSOLES F.

The diagnostic protocol of congenital uterine anomalies nowadays.

Fertil. Steril. 2008. 00:000-000.



Fétil. Steril.

RAGA,F; BONILLA F, SANZ-CORTES M, CASAÑ EM, BONILLA-MUSOLES F.

Reducing blood loss at myomectomy using a gelatin-thrombin matrix hemostatic sealant.

Fertil. Steril. 2008. 00:000-000.



J. Clin. Ultrasound

SANZ-CORTES M, RAGA,F; BONILLA-MUSOLES F.

Uterine arteriovenous malformations: Diagnosis and treatment based on our experience.

J. Clin. Ultrasound. 2008. 00:000-000.



Ultraschall Med.

RAGA,F; SANZ-CORTES M, CASAL EM, BONILLA-MUSOLES F.

First trimester sonographic diagnosis of autosomal recessive polycystic kidney disease.

Ultraschall Med. 2008. 00:000-000.



Ultrasound. Obstet. Gynecol.

RAGA,F; SANZ-CORTES,M; BONILLA-MUSOLES,F.

Three dimensional ultrasound diagnosis of ruptured subcapsular liver hematoma caused by HELLP syndrome.

Ultrasound. Obstet. Gynecol. 2008. 00:000-000.

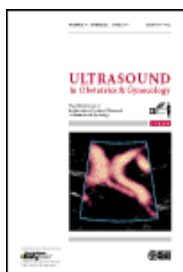

J. Obstet. Gynecol. Res.

RAGA,F; CASAÑ,EM ; BONILLA-MUSOLES,F;
POLAN,ML.

Gonadotropin-releasing hormone (GnRH) I regulation of interleukin (IL)-1B and IL-1 receptor antagonist expression in cultured human endometrial stromal cells.

J. Obstet. Gynecol. Res. 2008. 00:0000-0000.



Ultrasound. Obstet. Gynecol.

RAGA,F; BONILLA,F; SANZ-CORTES,M; BONILLA-MUSOLES,F.

Three-dimensional inversion mode rendering in molar pregnancy

Ultrasound. Obstet. Gynecol. 2008. 31:362-363.



J. Obstet. Gynecol. Res.

SANZ M, RAGA F, BONILLA-MUSOLES F.

Prenatal Diagnosis of congenital cystic adenomatoid malformation using three-dimensional inversion rendering; A case Report.

J. Obstet.Gynecol. Res. 2008. 00:000-000.



Rev. Españ. Ultrasonidos. Obst. Ginecol

SANZ-CORTES,M RAGA,F; NAVARRO,E; BONILLA-MUSOLES,F.

Desprendimiento total de amnios.

Rev. Españ. Ultrason. Obstet Ginecol. 2007, 1. (CD-ROM. SEGO).



Prenat. Diagn.

SANZ-CORTES,N; RAGA,F; BONILLA-MUSOLES,F.

Prenatal diagnosis of a 11q deletion síndrome associated with unilateral hydronephrosis diagnosed by 3D ultrasound examination.

Prenat. Diagn. 2007. 27:1158-1160.



J. Perinatal. Med.

SANZ-CORTES,M; RAGA,F; LEON,JL; SNIDERMAN,A; BONILLA-MUSOLES,F.

MRI and multiplanar 3D ultrasound compared in the prenatal assessment of enlarged posterior fossa.

J. Perinatal. Med. 2007. 35:422-424.




Prenat. Diagn.

SANZ-CORTES,M; RAGA,F; BONILLA-MUSOLES,F.

3D sonographic prenatal diagnosis of a lobar holoprosencephaly associated with cebocephaly.

Assessment and diagnosis with multiplanar reconstruction.

Prenat. Diagn. 2007. 27:585-586.



Prog. Obstet. Ginecol.

CASTILLO,JC; LEON,G; ZELAYA,A; RAGA,F; BONILLA-MUSOLES,F.

Aporte de diversos modos de ultrasonografía en 3D-4D al diagnóstico del hidrotórax fetal.

Prog. Obstet. Ginecol. 2007. 50:429-432.



Prog. Obstet. Ginecol.

BONILLA-MUSOLES,F; RAGA,F; BONILLA,F; DOLZ, M.

Apotación de la ecografía 3D al campo de la reproducción.

Prog. Obstet. Ginecol. 2007. 50:364-373.



Clin. Invest. Gin. Obst.

MARTIN,RM; RAGA,F; MARTIN,V; BONILLA-MUSOLES,F.

Gestación ectópica: Evolución diagnóstica y terapéutica en la última década.

Clin. Invest. Gin. Obstet. 2007.



Prog. Obstet. Ginecol.

CASTILLO,JC; LEON,G; ZELAYA,A; DOLZ,M; MACHADO,L; RAGA,F; BONILLA-MUSOLES,F.

Ultrasonidos. ¿A dónde vamos? Un esfuerzo por observar la vida intraútero más claramente.

Prog. Obstet. Ginecol. 2007. 50:216-223.



Rev. Iberoamer. Fétil.

SANZ-CORTES; DOLZ,M; ; RAGA,F; ABAD VELASCO,L; BONILLA-MUSOLES,F.

Gestación tubárica bilateral tras FIV en una paciente con factores de bajo riesgo para gestación ectópica.

Rev. Iberoamer. Fertil. 2007. 24:49-53.



Prenat. Diagn.

SANZ-CORTES,M; RAGA,F; CUESTA,A; CLARAMUNT,R; BONILLA-MUSOLES,F.

Prenatally detected double trisomy: Klinefelter and Down syndrome.

Prenat. Diagn. 2006. 26:1078-1080.




Clin. Invest. Gin. Obst.

RAGA,F; VENTO,M; SANZ,MC, BONILLA,F; CASAÑ,EM; BONILLA-MUSOLES,F.

Empleo prenatal de esteroides: riesgos y beneficios.

Clin. Invest. Gin. Obstet. 2006. 33:146-151.



Prog. Obstet. Ginecol.

SANZ-CORTES; MARTIN,V; RAGA,F; BONILLA-MUSOLES,F.

Neoplasia sincrónica de endometrio y ovario.

Prog. Obstet. Ginecol. 2006. 49:712-717.



Rev. Esp. Obstet. Ginecol.

LARREA,J; KUSHNER-DAVALOS,L; RAGA,F.

Anencefalia e hidrocefalia en embarazo gemelar posterior a fecundación in vitro.

Rev. Esp. Obstet. Ginecol. 2004. 1:155-157.



Rev. Esp. Obstet. Ginecol.

BENDAÑA,S; ABAD DE VELASCO,L; DOLZ,M; RAGA,F; BONILLA-MUSOLES,F.

Prevención del síndrome de hiperestimulación ovárica severo: Empleo de altas dosis de antagonista de la GnRH.

Rev. Esp. Obstet. Ginecol. 2004. 1:59-62.

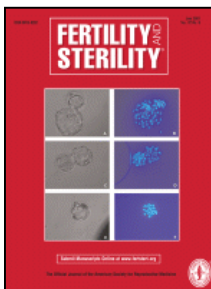

J. Gynecol. Surg.

BONILLA-MUSOLES,F; ABAD DE VELASCO, L; OSBORNE,NG; RAGA,F; BONILLA, F.

Two dimensional and three-dimensional ultrasound differential diagnosis of endometrial hyperplasia and endometrial adenocarcinoma.

J. Gynecol. Surg. 2003. 19:105-120.

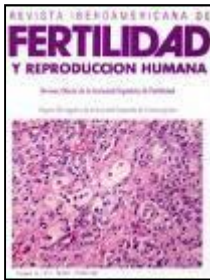

Fétil. Steril.

HUANG,HY; RAGA,F; WEN,Y; KRUESSEL,JE; POLAN,ML.

Interleukin-1B regulation of gonadotrophin-releasing hormone messenger ribonucleic acid in cultured human endometrial stromal cells.

Fertil. Steril. 2003. 79:399-406.



Rev. Iberoamer. Fertil.

LIMA-COUY,I; CABALLERO,O; MORENO,X;
CASAÑ,EM; RAGA,F; BONILLA-MUSOLES,F.

Ovodonación: situación actual en la medicina pública.
Rev. Iberoamer. Fertil. 2002. 19:321-334.

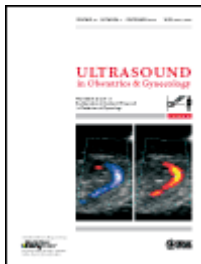

Prog. Obstet. Gynecol.

MONTAÑES,J; SANZ,C; PUIG,MJ; BONILLA,F;
RAGA,F.

Útero septo con duplicación cervical: una anomalía mülleriana infrecuente.

Prog. Obstet. Gynecol. 2002. 45:350-353.



Ultrasound. Obstet. Gynecol.

RAGA,F; BONILLA-MUSOLES,F; OSBORNE,NG;
CASAÑ,EM.

Congenital Müllerian anomalies: a review of currently available imaging modalities.

Ultrasound. Obstet. Gynecol. 2002. 2:56-67.

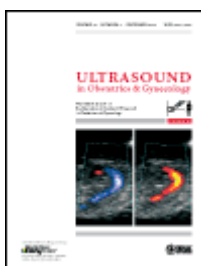

Giorn. It. Ost. Gin.

BONILLA-MUSOLES,F; SERRA,V; MACHADO,LE;
OSBORNE,NG; RAGA,F.

Diagnosi prenatale precoce ed ecografica tridimensionale transvaginale.

Giorn. It. Ost. Gin. 2002. 3:73-94.



Ultrasound. Obstet. Gynecol.

RAGA,F; BONILLA-MUSOLES,F; OSBORNE,NG;
CASAÑ,EM.

Communicating bicornuate uterus: successful reproductive outcome after in vitro fertilization and embryo transfer.

Ultrasound. Obstet. Gynecol. 2002. 2:68-72.



Prog. Obstet. Gynecol.

BONILLA-MUSOLES,F, RAGA,F.

Artrogriposis múltiple congénita (contracturas congénitas múltiples): Revisión.

Prog. Obstet. Ginecol. 2002. 45:150-156.

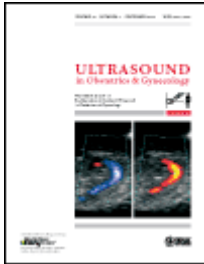

J. Clin. Ultrasound

BONILLA-MUSOLES,F; MACHADO,LE;
OSBORNE,NG; BLANES,J; RAGA,F.

Two-dimensional and three-dimensional sonography of conjoined twins.

J Clin Ultrasound. 2002. 30:68-75.



Ultrasound. Obstet. Gynecol.

BONILLA-MUSOLES,F; MACHADO,LE;
OSBORNE,NG; RAGA,F.

Morphologic assessment of the umbilical cord with three-dimensional ultrasonography.

Ultrasound. Obstet. Gynecol. 2002. 2:17-42.



Rev. Iberoamer. Fétil.

SANZ,C; RAGA,F; MONTAÑES,J; PUIG,MJ; BONILLA-MUSOLES,F.

Éxito reproductivo en el síndrome de Klinefelter.

Rev. Iberoamer. Fertil. 2002. 18:474-477.



Clin. Invest. Gin. Obstet.

PUIG,MJ; MONTAÑES,J; SANZ,C; ALFARO,L; RAGA,F;
BONILLA-MUSOLES,F.

Diagnostico precoz de fetos triploides.

Clin. Invest. Gin. Obst. 2002. 29:31-33.



Ultrasound. Obstet. Gynecol.

BONILLA-MUSOLES,F; MACHADO,L; RAGA,F;
OSBORNE,NG; BONILLA JR, F.

Prenatal diagnosis of sacrococcygeal teratomas by two- and three-dimensional ultrasound.

Ultrasound. Obstet. Gynecol. 2002. 19:200-205.



Ultrasound Q.

MACHADO,LE; BONILLA-MUSOLES,F; RAGA,F;
OSBORNE, NG.

Thanatophoric dysplasia: Ultrasound diagnosis.

Ultrasound Q. 2001. 17:235-243.




Prog. Obstet. Ginecol.

SANZ,C; PUIG,MJ; MONTAÑES,J; CASAÑ,EM;
RAGA,F.

Gestación heterotópica: tratamiento conservador y evolución favorable de la gestación intrauterina.

Prog. Obstet. Ginecol. 2001. 44:439-442.



J. Clin. Endocrinol. Metab.

HUANG,HY; WEN,Y; RAGA,F; KRUESSEL,JE;
POLAN,ML.

Interleukin (IL)-1B regulation of IL-1B and IL-1 receptor antagonist expression in cultured human endometrial stromal cells.

J. Clin. Endocrinol. Metab. 2001. 86:1387-1397.



Prog. Obstet. Ginecol.

BONILLA-MUSOLES,F; RAGA,F; BLANES,J;
OSBORNE,NG; MACHADO,LE.

Ecografía tridimensional en uroginecología.

Prog. Obstet. Ginecol. 2001. 44:237-244.



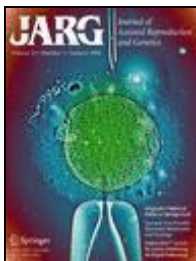Acta Ginecológica.

BONILLA-MUSOLES,F; RAGA,F; GOMES,E; IBERICO,G.
Antagonistas de la GnRH en reproducción.
Acta Ginecológica. 2001. LVIII:33-44.



J. Ultrasound. Med.

BONILLA-MUSOLES,F; MACHADO,LE; OSBORNE,NG;
RAGA,F.
Abdominal wall defects.
J. Ultrasound. Med. 2001. 20:379-389.



J. Assist. Reprod. Genet.

HUANG,HY; RAGA,F; KRUESSEL,JE; POLAN,ML.
Gonadotrophin-releasing hormone messenger ribonucleic acid and protein expression in Vero cells.
J. Assist. Reprod. Genet. 2001. 18:268-275.



Prenat. Diagn.

BONILLA-MUSOLES,F; MACHADO,LE; RAGA,F;
OSBORNE,NG.
Two- and Three-dimensional ultrasound in malformations of the medullary canal: report of four cases.
Prenat. Diagn. 2001. 21:622-626.



J. Ultrasound. Med.

BONILLA-MUSOLES,F; MACHADO,LE; RAGA,F;
OSBORNE,NG.
Fetus acardius: Two- and Three-dimensional ultrasound diagnoses.
J. Ultrasound. Med. 2001. 20:1117-1127.




J. Clin. Endocrinology. Metab.

CASAÑ,EM; RAGA,F; BONILLA-MUSOLES,F;
POLAN,ML.

**Human oviductal gonadotrophin-releasing hormone:
possible implications in fertilization, early embryonic
development and implantation.**

J. Clin. Endocrinol. Metab. 2000. 85:1377-1381.



Cuad. Med. Reprod.

BONILLA-MUSOLES,F; SERRA,V; BLANES,J; RAGA,F.
Tridimensión y diagnóstico prenatal.

Cuad. Med. Reprod. 2001. 7:123-.138.



Middle. East. Fétil. Soc. J.

BONILLA-MUSOLES,F; RAGA,F; BLANES,J;
NAVARRO,J.

**Current state of three-dimensional ultrasound in
reproductive medicine.**

Middle East Fertil. Soc. J. 2000. 5:169-177.



Ultrasound Q.

OSBORNE,NG; BONILLA-MUSOLES,F; RAGA,F;
BONILLA.F.

**Umbilical cord cysts: color Doppler and three-
dimensional ultrasound evaluation.**

Ultrasound Q. 2000. 16:133-139.



Ultrasound Q.

BONILLA-MUSOLES,F; MACHADO,LE;
OSBORNE,NG; RAGA,F; CHAMUCA,L; CHAGAS,K.

Ultrasound diagnosis of facial and cephalic pole malformations: comparative study of different three-dimensional modalities and two-dimensional ultrasound.

Ultrasound Q. 2000. 16:97-105.



GO. Actual.

BONILLA-MUSOLES,F; RAGA,F; BLANES,J;
OSBORNE,NG.

Estudo comparativo entre angiografía digital Doppler e Doppler colorido em ginecología e obstetricia. Parte II.

GO. Actual. 2000. 4:34-42.




GO. Actual.

BONILLA-MUSOLES,F; RAGA,F; BLANES,J.

Estudo comparativo entre angiografía digital Doppler e Doppler colorido em ginecología e obstetricia. Parte I.

GO. Actual. 2000. 4:10-18.




Cuad. Med. Reprod.

IZQUIERDO,D; BONILLA-MUSOLES,F; RAGA,F;
CASAÑ,EM; BLANES,J.

Angiografía digital Doppler.

Cuad. Med. Reprod. 1999. 5:193-203.




Cuad. Med. Reprod.

OSBORNE,NG; BONILLA-MUSOLES,F; VERGARA,F;
BAILAO,LE; RAGA,F.

Marcadores ecográficos de infección fetal..


Cuad. Med. Reprod. 1999. 5:205-231.



Cuad. Med. Reprod.

MACHADO,L; BONILLA-MUSOLES,F; VERGARA,F;
RAGA,F; BLANES,J.

Diagnostico de las displasias tanatofóricas: ayuda de la tridimensión.
Cuad. Med. Reprod. 1999. 5:161-170.




Cuad. Med. Reprod.

MACHADO,LE; BONILLA-MUSOLES,F; RAGA,F;
VERGARA,F; BLANES,J.

Disostosis de las extremidades: ayuda de la tridimensión.

Cuad. Med. Reprod. 1999. 5:135-159.




Cuad. Med. Reprod.

BONILLA-MUSOLES,F; VERGARA,F; BLANES,J;
RAGA,F.

Teratoma sacrococcigeo: aporte de la tridimensión.

Cuad. Med. Reprod. 1999. 5:127-133.




Cuad. Med. Reprod.

BONILLA-MUSOLES,F; MACHADO,LE; BLANES,J;
RAGA,F.

Defectos de la pared abdominal: ayuda de la tridimension.

Cuad. Med. Reprod. 1999. 5:117-126.




Cuad. Med. Reprod.

BONILLA-MUSOLES,F; MACHADO,LE;
CHAMUSCAL,K; RAGA,F.

Hidrocefalia: aporte de la ecografía tridimensional.

Cuad. Med. Reprod. 1999. 5:111-116.




Cuad. Med. Reprod.

MACHADO,LE; CHAMUSCAL,K; BONILLA-
MUSOLES,F; RAGA,F.

Ecografía tridimensional (3D) en tiempo “quasi” real en la segunda mitad del embarazo.

Cuad. Med. Reprod. 1999. 5:87-110.




Cuad. Med. Reprod.

BONILLA-MUSOLES,F; RAGA,F; MACHADO,LE;
OSBORNE,NG.

Ecografía tridimensional interactiva (3D) y Doppler color en la gestación inicial normal y patológica.

Cuad. Med. Reprod. 1999. 5:54-86.

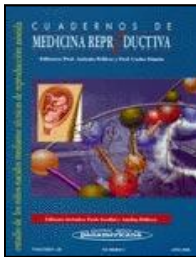


Cud. Med. Reprod.

RAGA,F; BONILLA-MUSOLES,F; CASAÑ,EM;
OSBORNE,NG.

Malformaciones congénitas de los conductos de Müller: posibilidades diagnosticas 3D.

Cuad. Med. Reprod. 1999. 5:33-52.



Cuad. Med. Reprod.

RAGA,F; BONILLA-MUSOLES,F; CASAÑ,EM;
OSBORNE,NG.

Ecografía tridimensional interactive en medicina reproductive.

Cuad. Med. Reprod. 1999. 5:15-32.



Obstet. Ginecol. Españ.

BONILLA,F; RAGA,F; CASAÑ,EM; BONILLA-MUSOLES,F.

Uteros comunicantes: raras anomalias müllerianas.

Obst. Gynecol. Españ. 1999. 8:127-130.

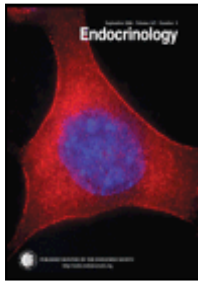


J. Gynecol. Surg.

BONILLA-MUSOLES,F; OSBORNE,NG; RAGA,F;
BLANES,J.

Color Doppler angiography and color Doppler frequency use in obstetrics and gynecology.

J. Gynecol. Surg. 1999. 15:27-39.



Endocrinology.

RAGA,F; CASAÑ,EM; KRUESSEL,JS; WEN,Y;
POLAN,ML.

**The role of Gonadotropin-releasing hormone in Murine
primplantation embryonic development.**

Endocrinology. 1999; 40:3705-3712.



J. Ultrasound. Med.

DOLZ,M; OSBORNE,NG; RAGA,F; BONILLA-
MUSOLES,F.

**Polycystic ovarian syndrome: Assessment with color
Doppler angiography and three-dimensional
ultrasonography.**

J. Ultrasound. Med. 1999. 18:303-313.

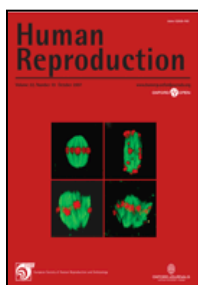

Mol. Hum. Reprod.

KRUSSEL,JE; CASAÑ,EM; RAGA,F; WEN,Y;
HUANG,HY; POLAN,ML.

**Expresión of mRNA for vascular endotelial growth
factor transmembranous receptors Flt1 and KDR, and
the soluble receptor sflt in cyclic human endometrium.**

Mol. Hum. Reprod. 1999. 5:452-458.



Hum. Reprod.

RAGA,F; BONILLA-MUSOLES,F; CASAÑ,EM;
KLEIN,O; BONILLA,F,.

**Asessment of endometrial volume by three-dimensional
ultrasound prior to embryonic transfer: clues to
endometrial receptivity.**

Hum. Reprod. 1999. 14:2851-2854.



Obstet. Ginecol. Españ.

MACHADO,LE; BONILLA-MUSOLES,F; RAGA,F;
BONILLA,F.

**Diagnostico de toracopagos mediante el empleo de
ecografía tridimensional.**

Obst. Ginecol. Españ. 1999. 8:19-27.

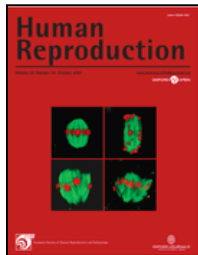

J. Clin. Endocrinol. Metab.

RAGA,F; CASAÑ,EM; WEN,Y; POLAN,ML.

Independent regulation of Matrix Metalloproteinase-9 (MMP-9) and Tissue inhibitor of Metalloproteinase-1 (TIMP-1), and -3 (TIMP-3), in human endometrial stromal cells by gonadotropin-releasing hormone: Implications in early human pregnancy.

J. Clin. Endocrinol. Metab. 1999. 84:636-642.



Hum Reprod.

RAGA,F; CASAÑ,EM; BONILLA,F; BONILLA-MUSOLES,F.

Recombinant follicle stimulating hormone stimulation in poor responders with normal basal levels of follicle-stimulating hormone and oestradiol.

Hum. Reprod. 1999. 14:1431-1434.



Mol. Hum. Reprod.

CASAÑ,EM; RAGA,F; POLAN,ML.

Gonadotropin-releasing hormone mRNA and protein expression in preimplantation human embryos.

Mol. Hum. Reprod. 1999. 5:231-239.



Obstet. Ginecol. Españ.

MACHADO,LE; CHAMUSCA,L; BONILLA-MUSOLES,F; RAGA,F;

Ecografía tridimensional (3D) en tiempo “quasi real” en la segunda mitad del embarazo.

Obst. Gynecol. Españ. 1999. 8:7-18.

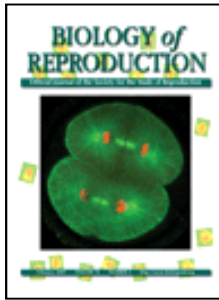

Obstet. Ginecol. Españ.

RAGA,F; CASAÑ,EM; BONILLA-MUSOLES,F; PELLICER,A.

Terapéuticas de compensación en tratamientos a largo plazo con análogos de la GnRH.

Obst. Ginecol. Españ. 1998. 7:107-116.



Biol. Reprod.

RAGA,F; CASAÑ,EM; KRUESSEL,JS; WEN,Y;
NEZHAT,C; POLAN,ML.

Quantitative Gonadotropin-releasing hormone gene expression and immunohistochemical localization in human endometrium throughout the menstrual cycle.

Biol. Reprod. 1998. 59:661-669.

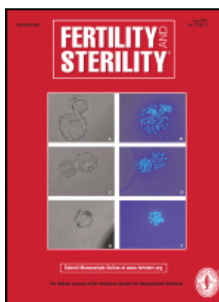

J. Ultrasound. Med.

BONILLA-MUSOLES,F; RAGA,F; VILLALOBOS,A;
OSBORNE,NG.

First-trimester neck abnormalities: Three-dimensional evaluation.

J. Ultrasound. Med. 1998. 17:419-425.




Fertil. Steril.

CASAÑ,EM; RAGA,F; KRUESSEL,JS; WEN,Y;
NEZHAT,C; POLAN,ML.

Immunoreactive gonadotropin-releasing hormone expression in cyclic human endometrium of fertile patients.

Fertil. Steril. 1998. 70:102-106.



J. Natl. Med. Assoc.

BONILLA-MUSOLES,F; RAGA,F; BONILLA,F;
BLANES,F; OSBORNE,NG.

Early diagnosis of conjoined twins using two-dimensional color Doppler and three-dimensional ultrasound.

J. Natl. Med. Assoc. 1998. 90:552-556.




Obstet. Ginecol. Españ.

BONILLA-MUSOLES,F; RAGA,F; ROSCISZEWSKI,V;
BAILAO,LA.

Ecografía Doppler color, Doppler amplitud y tridimensión en el estudio de la mama.

Obst. Gynecol. Españ. 1998. 7:85-105.



J. Am. Assoc. Gynecol. Laparosc.

NEZHAT,CH; BASTIDAS,JA; PENNINGTON,E;
RAGA,F; NEZHAT,CR.

Laparoscopic treatment of type IV rectovaginal fistula.

J. Am. Assoc. Gynecol. Laparosc. 1998. 5:297-299.



Acta. Obstet. Gynecol.

RAGA,F; BAUSET,C; REMOHI,J; BONILLA-
MUSOLES,F.

**Efecto sobre la reproducción de las anomalias
mullerianas congénitas.**

Acta. Obstet. Gynecol. 1998. 2:50-51.



Rev. Iberoamer. Fertil.

RAGA,F; CASAÑ,EM.

**Análogos de la GnRH en reproducción asistida: Una
promesa cumplida.**

Rev. Iberoamer. Fertil. 1998. 3:209-215.



Obstet. Ginecol. Españ.

CASAÑ,EM; RAGA,F; BONILLA-MUSOLES,F.

GnRH placentaria: La gran desconocida.

Obst. Gynecol. Españ. 1997. 6:13-16.

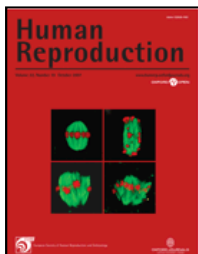

J. Gynecol. Surg.

BONILLA-MUSOLES,F; RAGA,F; BLANES,J;
OSBORNE,NG.

Three-dimensional hysterosonographic evaluation of the normal endometrium: comparison with transvaginal sonography and three-dimensional ultrasound.

J. Gynecol. Surg. 1997. 13:101-107.



Hum. Reprod.

RAGA,F; BAUSET,C; SIMON,C; BONILLA-MUSOLES,C; PELLICER,A.

Reproductive impact of congenital Müllerian anomalies.

Hum. Reprod. 1997. 12:2277-2281.



Obstet. Ginecol. Españ.

BONILLA-MUSOLES,F; RAGA,F; BLANES,J;
COELHO,F.

Estado actual de la visión tridimensional del embrión y del feto en las primeras 14 semanas.

Obst. Ginecol. Españ. 1997. 6:55-63.




Rev. Iberoamer. Fértil.

BONILLA-MUSOLES,F; RAGA,F; BLANES,F;
OSBORNE,NG.

Avances en el diagnóstico prenatal: Empleo de la angiografía digital Doppler y la tridimensión ecográfica.

Rev. Iberoamer. Fertil. 1997. 14:295-318.



Prog. Diagn. Prenat.

BONILLA-MUSOLES,F; RAGA,F; VILLALOVOS,A;
COELHO,F.

New technologies in the diagnosis of hygroma colli.

Prog. Diagnost. Prenat. 1997. 9:329-344.



Obstet. Ginecol. Españ.

BONILLA-MUSOLES,F; BALLESTER,MJ; RAGA,F;
BLANES,J.

Revisión: El Doppler color transvaginal (DCT) y la angiografía digital Doppler (ADD) en la patología endometrial. Situación actual del problema.

Obst. Ginecol. Españ. 1997. 6:65-84.



Gynecol. Oncol.

**BONILLA-MUSOLES,F; RAGA,F; OSBORNE,NG.
Three-dimensional hysterosonography for the study of endometrial tumors: Comparison with conventional transvaginal ultrasonography, hysterosalpingography, and hysteroscopy.**

Gynecol. Oncol. 1997. 65:245-252.



Obstet. Ginecol. Españ.

**RAGA,F; CASAÑ,EM; BONILLA-MUSOLES,F.
Administración inadvertida de análogos de la GnRH (Acetato de leuprolina) en pacientes gestantes.**

Obst. Ginecol. Españ. 1997. 6:17-19.



Obstet. Ginecol. Españ.

**BONILLA-MUSOLES,F; RAGA,F; BLANES,J.
Doppler color transvaginal en el leiomioma de la trompa de falopio.**

Obst. Ginecol. Españ. 1997. 6:29-30.



Obstet. Ginecol. Españ.

**BONILLA-MUSOLES,F; RAGA,F; BLANES,J.
Embarazo tubarico gemelar unilateral: Diagnostico con Doppler color transvaginal.**

Obst. Ginecol. Españ. 1997. 6:1-3.




J. Gynecol. Surg.

**BONILLA-MUSOLES,F; RAGA,F; BLANES,J;
BAILAO,LA; OSBORNE,NG.**

Sonohysterosalpingography with transvaginal color Doppler and three-dimensional ultrasound: State of the art.

J. Gynecol. Surg. 1996. 12:227-240.

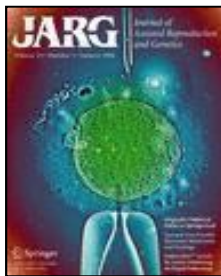

Rev. Esp. Quimioterap.

LÓPEZ-HONTANGAS, JL; BLANES, J; RAGA, F;
BONILLA-MUSOLES, F.

Toxoplasmosis congénita: Enfoque diagnóstico y aproximación terapéutica actual.

Rev. Esp. Quimioterap. 1996. 9:109-120.




J. Assist. Reprod. Genet.

RAGA, F; BONILLA-MUSOLES, F; OSBORNE, NG.

Uterine anomalies with three-dimensional ultrasound (Müllerian duct malformations)”

J. Assist. Reprod. Genet. 1996. 6:126-141.



J. Natl. Med. Assoc.

RAGA, F; BALLESTER, MJ; OSBORNE, N; BONILLA-MUSOLES, F.

Subchorionic placental cyst: A cause of fetal growth retardation-Ultrasound and color flow Doppler diagnosis and follow up.

J. Natl. Med. Assoc. 1996. 88:265-288.



J. Clin. Ultrasound.

BONILLA-MUSOLES, F; RAGA, F; OSBORNE, N;
BLANES, J.

Control of intrauterine device insertion with three-dimensional ultrasound: Is it the future?.

J. Clin. Ultrasound. 1996. 24:263-267.



Core J.

RAGA,F; BONILLA-MUSOLES,F; BLANES,J;
OSBORNE,NG.

Anomalías congénitas del conducto de Müller.

Core J. 1996. 3:26-27.




Clin. Invest. Gin. Obstet.

De GONZALO,A; RAGA,F; BALLESTEROS,A;
COMPANY,A; CERDA,M.

Gestación ectópica persistente.

Clin. Invest. Gin. Obst. 1996. 23:420-423.




J. Natl. Med. Assoc.

RAGA,F; OSBORNE,N; BALLESTER,MJ; BONILLA-
MUSOLES,F.

**Color flow Doppler: A useful instrument in the
diagnosis of funic presentation.**

J. Natl. Med. Assoc. 1996. 88:94-96.




Fétil. Steril.

RAGA,F; BONILLA-MUSOLES,F; BLANES,J;
OSBORNE,N.

**Congenital Müllerian anomalies: diagnostic accuracy
of three-dimensional ultrasound.**

Fertil. Steril. 1996. 65:523-528.



Core J.

BONILLA-MUSOLES,F; RAGA,F; OSBORNE,NG.

**Evaluación ecográfica tridimensional de masas
ovaricas.**

Core J. 1996. 1:27-28.



J. Reprod. Med..

RAGA,F; BALLESTER,MJ; OSBORNE,N; BONILLA-
MUSOLES,F.

Role of color flow Doppler ultrasonography in diagnosing velamentous insertion of the umbilical cord and vasa previa.


J. Reprod. Med. 1995. 40:804-808.



Gynecol. Oncol.

BONILLA-MUSOLES,F; RAGA,F; OSBORNE,N.
Three-dimensional ultrasound evaluation of ovarian masses.

Gynecol. Oncol. 1995. 59:129-135.



Prog. Diagnost. Prenat.

BONILLA-MUSOLES,F; RAGA,F; BALLESTER,MJ.
Diagnostico con endosonografia vaginal de las malformaciones embrionarias: comparación con los hallazgos cromosómicos.

Prog. Diagnost. Prenat. 1995. 7:139-163.



J. Ultrasound Med.

BONILLA-MUSOLES,F; RAGA,F; OSBORNE,N;
BLANES,J.

Use of three-dimensional ultrasonography for the study of normal and pathologic morphology of the human embryo and fetus.

J. Ultrasound. Med. 1995. 14:757-765.



Hum. Reprod. Update..

BONILLA-MUSOLES,F; RAGA,F; BLANES,J;
OSBORNE,N; SILES,C.

Three-dimensional ultrasound in reproductive medicine. Preliminary report.

Hum. Reprod. Update. 1995. 1:429-435.



Ginecologia Obstetricia

BONILLA-MUSOLES,F; RAGA,F; BLANES,J.

Tridimensao ecográfica em Obstetricia e Ginecologia. Futuro da nossa especialidade?

Ginecologia Obstetricia. 1995. 4:28-71.



Obstet. Ginecol. Españ.

BONILLA-MUSOLES,F; RAGA,F; BLANES,J;
COELHO,F.

La tridimensión ecográfica en tumores ováricos.

Obst. Ginecol. Españ. 1995. 4:193-210.



J. Ultrasound. Med.

BONILLA -MUSOLES,F; BALLESTER,MJ; RAGA,F.
Normal uterine arterial blood flow in postmenopausal women assessed by transvaginal color Doppler ultrasonography.

J. Ultrasound. Med. 1995. 14:491-494.



J. Ultrasound. Med.

BONILLA-MUSOLES,F; BALLESTER,MJ; RAGA,F.
Transvaginal color Doppler assessment of endometrial status in normal postmenopausal women: The effect of hormone replacement therapy.

J. Ultrasound. Med. 1995. 14:503-507.



J. Ultrasound. Med.

BONILLA-MUSOLES,F; BALLESTER,MJ; RAGA,F.
Normal uterine arterial blood flow in postmenopausal women assessed by transvaginal color Doppler sonography: the effect of hormonal replacement therapy.

J. Ultrasound. Med. 1995. 14:497-501.




Rev. Iberoamer. Fertil.

BONILLA-MUSOLES,F; BLANES,J; BAILAO,A;
BALLESTER,MJ; OSBORNE,N; and RAGA,F.

Ecografía abdominal, vaginal, color doppler transvaginal y tridimensional en el diagnóstico de la endometriosis.

Rev. Iberoamer. Fertil. 1995. 4:55-71.




Ultraschall in Med

RAGA,F; BALLESTER,MJ; BONILLA-MUSOLES,F.

Extraamniotische Schwanger-schaft.

Ultraschall in Med. 1995. 16:29-32.



J. Assist. Reprod. Genet.

BONILLA-MUSOLES,F; RAGA,F; OSBORNE,N;

PELLICER,A; BLANES,J.

Use of three-dimensional ultrasound in reproductive medicine.

J. Assist. Reprod. Genet. 1995. 5:170-188.




J. Ultrasound. Med.

BONILLA-MUSOLES,F; BALLESTER,MJ; TARIN,J;

RAGA,F; OSBORNE,N; PELLICER,A.

Does transvaginal color Doppler sonography differentiate between developing and involuting ectopic pregnancies?.

J. Ultrasound. Med. 1995. 14:175-181.



J. Assist. Reprod. Genet.

BONILLA-MUSOLES,F; BALLESTER,MJ; RAGA,F;

BLANES,J.

Transvaginal color Doppler sonography from folliculogenesis to implantation: Normal and abnormal evolution.

J. Assist. Reprod. Genet. 1995. 5:158-169.



Revista Brasileira de Gine. Obst.

RIBEIRO,JAC; BALLESTER,MJ; SANCHEZ,RC;

RAGA,F; BONILLA-MUSOLES.

Estudo Dopplerfluxometrico dos leiomiomas uterinos.

Revista Brasileira de Gine.Obst. 1995. 16:101-108.



Obstet. Ginecol. Españ.

BONILLA-MUSOLES,F; BALLESTER,MJ; RAGA,F;
BLANES,J.

Doppler color transvaginal (DCT), desde la foliculogénesis a la implantación. Posibilidades de control evolutivo.

Obst. Ginecol. Españ. 1994. 3:169-182.



Obstet. Ginecol. Españ.

BONILLA-MUSOLES,F; BALLESTER,MJ; RAGA,F;
CRESPO-RIBEIRO,JA; BLANES,J; CORONADO,R.

Doppler color transvaginal en tumoraciones pélvicas.

Obst. Ginecol. Españ. 1994. 3:57-74.

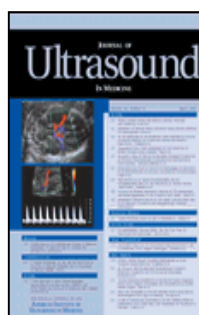

Acta Obstet. Gynecol. Scand.

BALLESTER,MJ; RAGA,F; SERRA,V; BONILLA-MUSOLES,F.

Early prenatal diagnosis of an ominous aneurisma of the vein of Galen by color Doppler ultrasound.

Acta Obstet. Gynecol. Scand. 1994. 73:592-595.



J. Ultrasound. Med.

BONILLA-MUSOLES,F; RAGA,F; BALLESTER,MJ;
SERRA,V.

Early detection of embryonic malformations by transvaginal and color Doppler sonography.

J. Ultrasound. Med. 1994. 13:347-356.



Obstet. Ginecol. Españ.

RAGA,F; MONTEAGUDO,C; BALLESTER,MJ;
BALLESTEROS,A; BONILLA-MUSOLES,F.

Carcinoma tubárico primario: Caso clínico y revisión de conjunto.

Obst. Ginecol. Españ. 1994. 3:225-231.



Obstet. Ginecol. Españ.

BONILLA-MUSOLES,F; RAGA,F; BLANES,J;
OSBORNE,N.

Revision de conjunto: la tridimensión ecográfica y sus aplicaciones en obstetricia y ginecología.

Obst. Ginecol. Españ. 1994. 3:233-250.



Obstet. Ginecol. Españ.

BALLESTEROS,A; RAGA,F.

Patología de la implantación (II).

Obst. Ginecol. Españ. 1994. 3:197-200.



Obstet. Ginecol. Españ.

BALLESTEROS,A; RAGA,F.

Patología de la implantación (I).

Obst. Ginecol. Españ. 1994. 3:189-195.



Gine. Dips.

BONILLA-MUSOLES,F; BALLESTER,MJ; RAGA,F;
SIMON,C.

Aplicaciones del Doppler color transvaginal.

Gine. Dips. 1993. 2:67-91.



J. Ultrasound. Med

BONILLA-MUSOLES,F; BALLESTER,MJ; SIMON,C;
SERRA,V; RAGA,F.

Is avoidance of surgery possible in patients with perimenopausal ovarian tumors using transvaginal ultrasound?.

J. Ultrasound. Med. 1993. 12:33-39.




Ultraschall in Med.

RAGA,F; SIMON,C; STRASSER,J; BONILLA-MUSOLES,F.

Abdominale, perineale und vaginale sonographische diagnose der Zervikaleninsuffizienz.

Ultraschall in Med. 1992. 13:24-27.



Rev. FCASOG.

BONILLA-MUSOLES,F; BALLESTER,MJ; RAGA,F; SERRA,V; SIMON,C.

Aplicaciones del Doppler Duplex Color Transvaginal en Obstetricia y Ginecología.

Rev. FCASOG. 1992. 2:9-22.



Obst. Ginecol. Españ.

BONILLA-MUSOLES,F; BALLESTER,MJ; RAGA,F; SERRA,V; SIMON,C; TORTAJADA,M.

Aplicaciones del Doppler Color Transvaginal en Obstetricia y Ginecología.

Obst. Ginecol. Españ. 1992. 2:143-154.



Pren. Med. Argentina.

BONILLA-MUSOLES,F; BALLESTER,MJ; RAGA,F; SERRA,V; SIMON,C.

Aplicaciones del Doppler Duplex color transvaginal en Obstetricia y Ginecología.

Pren. Med. Argentina. 1992. 79:346-356.



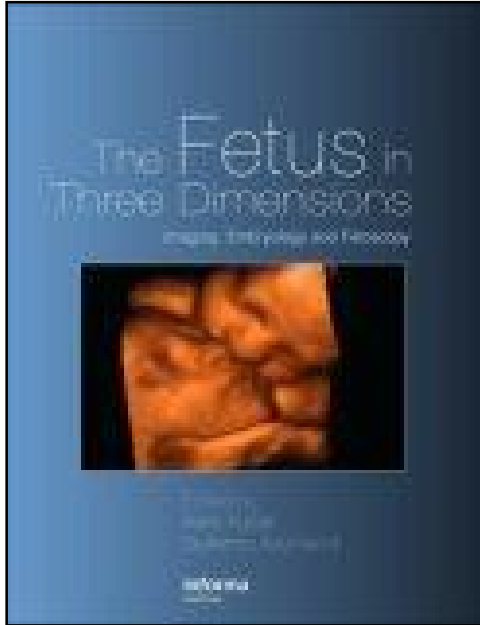
Geburtsh. u. Frauenheilk.

SIMON,C; RAGA,F; STRASSER,J; BONILLA-MUSOLES,F.

Histerosalpingographie: Synechien? Gärtnersche Gänge?.

Geburtsh. Frauenheilk. 1990. 50:977-981.

THE FETUS IN THREE DIMENSIONS.
IMAGING, EMBRYOLOGY AND
FETOSCOPY.



I.S.B.N: 04-1537-523-1

BONILLA-MUSOLES,F; MACHADO,L; **RAGA,F.**

Gastrosintestinal tract and internal abdominal wall.

The fetos in three dimensions. Imaging, embryology and fetoscopy.

Ed.Healthcare. Abindon. Inglaterra. 2007. pp:287-308.

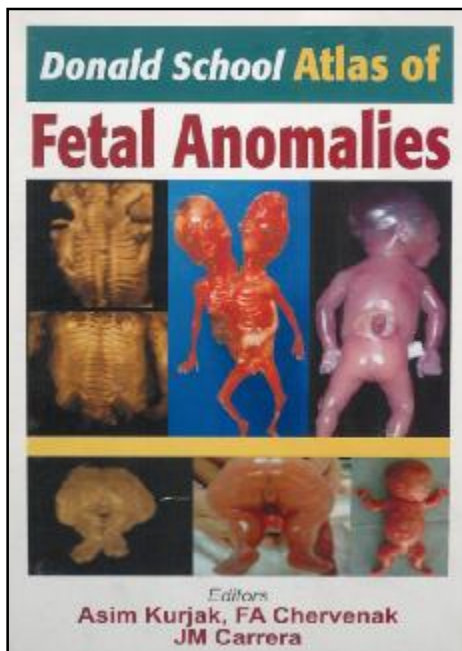
BONILLA-MUSOLES,F; MACHADO,L; **RAGA,F.**

Skelletal anomalies.

The fetos in three dimensions. Imaging, embryology and fetoscopy.

Ed.Healthcare. Abindon. Inglaterra. 2007. pp:331-346.

DONALD SCHOOL ATLAS OF FETAL MALFORMATIONS.




I.S.B.N: 81-8061-919-2

BONILLA-MUSOLES,F; MACHADO,L; **RAGA,F.**

Gastrointestinal tract and internal abdominal wall.

Donald school atlas of fetal malformations. Ed.Jaypee. New Delhi. 2007.
pp:174-194.


TEXTBOOK OF PERINATAL MEDICINE.



I.S.B.N: 84-7986-598-9

BONILLA-MUSOLES,F; MACHADO,L; **RAGA,F.**
3D, 4D ultrasound evaluation of the embryo and the early fetus.
Textbook of perinatal medicine. Ed.Taylor and Francis. Londres.
Inglaterra. 2005. pp:285-313.

ATENCIÓN TEMPRANA. DESARROLLO INFANTIL, TRANSTORNOS E INTERVENCIÓN.



I.S.B.N: 84-7986-598-9


RAGA,F; CASAÑ,EM; BONILLA-MUSOLES,F.

Aspectos obstétricos y ginecológicos. Consulta preconcepcional.

Atencion temprana. desarrollo infantil, transtornos e intervencion.

Ed.Promolibro. Valencia. España. 2005. pp:55-68.

AN ATLAS OF THREE AND FOUR DIMENSIONAL SONOGRAPHY IN OBSTETRICS AND GYNECOLOGY.




I.S.B.N: 81-8061-198-1

BONILLA-MUSOLES,F; MACHADO,L; **RAGA,F.**

Three and four dimensional images of fetal malformations.

An atlas of three and four dimensional sonography in obstetrics and gynecology. Ed.Jaypee. New Delhi. India. 2004. pp:480-499.

ECOGRAFIA PRACTICA EN OBSTETRICIA Y GINECOLOGIA (SESEGO).



I.S.B.N: 84-922585-5-1

RAGA,F.

Ecografía tridimensional en obstetricia.

Ecografía práctica en obstetricia. Ed.Encuentros profesionales. Madrid. España. 2004. pp:199-202.

RAGA,F.

Técnicas invasivas en el diagnóstico prenatal ecográfico.

Ecografía práctica en obstetricia. Ed.Encuentros profesionales. Madrid. España. 2004. pp:203-2008.